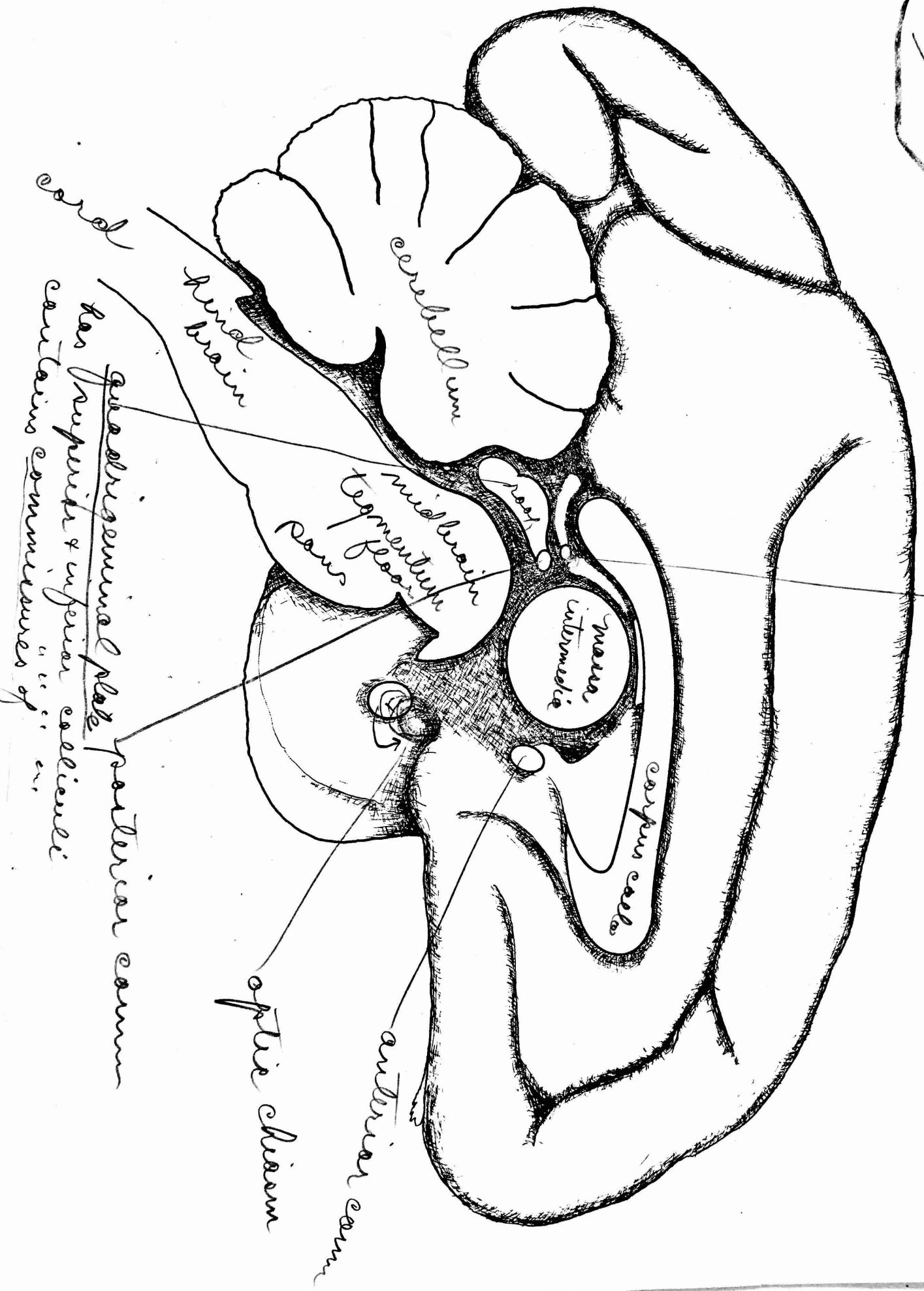


Monkey



olbulos comm.

cord

has superior & inferior colliculi

contains commissures of

subcallosal plate

posterior comm.

anterior comm.

optic chiasm

massa intermedia

corpus callosum

mid brain

hind brain

cerebellum

Monkey