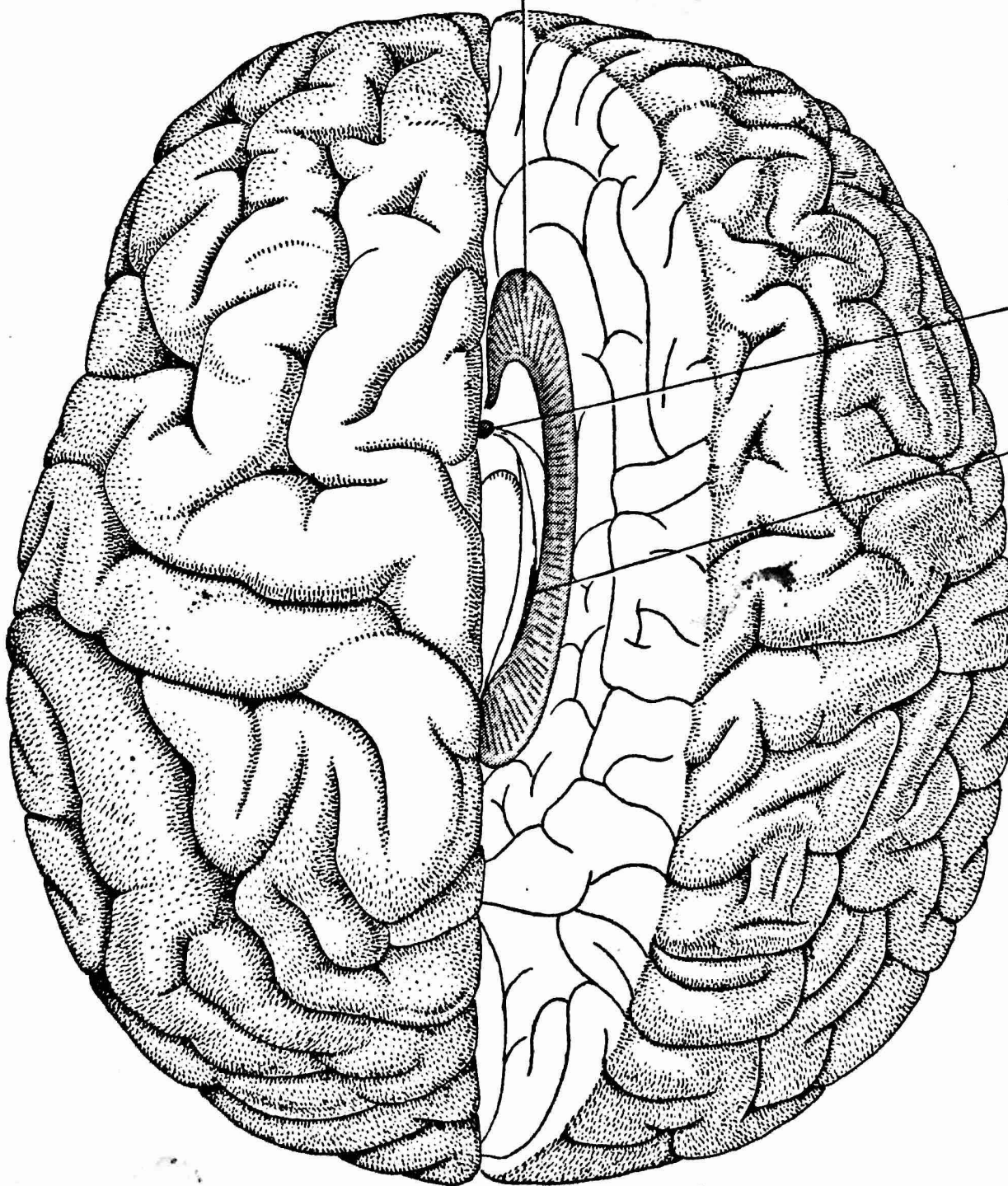


CORPUS
CALLOSUM



ANTERIOR
COMMISSURE

HIPPOCAMPAL
COMMISSURE

TWO HEMISPHERES of the human brain are divided by neurosurgeons to control epileptic seizures. In this top view of the brain the right hemisphere is retracted and the corpus callosum and other commissures, or connectors, that are generally cut are shown in color.