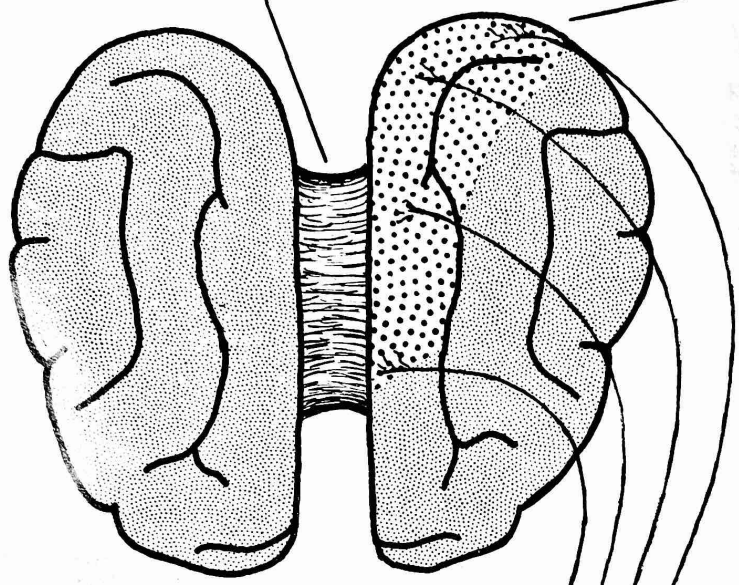


Corpus callosum

Visual cortex



Optic radiation

Superior colliculus

L. geniculate nucleus

Pretectal area

Chiasma

